EXAM COMMITTEE

12TH BATCH

NEU TBL -2

You can find the explanation on youtube !!

https://www.youtube.com/watch?v=XdIW9UAmLq4&list=PLqjMlRWBVQpbwysyUQlhNfoIurqndtE4k&index=4

1. A 20-year-old married has been diagnosed with generalized tonic-clonic seizures. She is on oral contraceptives. You are thinking of prescribing phenytoin to her. Which one of the following considerations, you must take into account before prescribing phenytoin to her?

A. Give supplements of vitamin B12
B. Obtain baseline CBC and LFTs before starting phenytoin
C. Phenytoin is contraindicated in women of child-bearing age
D. Start with low dose of phenytoin to avoid toxicity
E. Switch to other non-hormonal contraceptive method

Ans: C

2. A patient is prescribed alprazolam to treat her panic disorder. Binding at which site produces the drug's action?

A. Melatonin receptors
B. 5-HTID receptors
C. Opioid receptors
D. GABAA receptors at the interface of and Y2 subunits
E. Histamine HI receptors

Ans: D

3. Comparing levo-dopa therapy with dopamine agonist therapy for the management of Parkinson's disease, which of the following side effects are more pronounced with dopamine agonist?

A. Nausea and anorexia
B. Postural hypotension
C. Anxiety and depression
D. Tachycardia
E. dyskinesia

Ans: C

4. A 58 year old woman was driving her car when she had the sudden onset of a severe headache. She pulled into a service station and stopped the car. Then, she slumped over the wheel. She was taken to the emergency room where she remained comatose and died hours later. The gross appearance of her brain found at autopsy is attached. Which of the following is the most likely diagnosis?

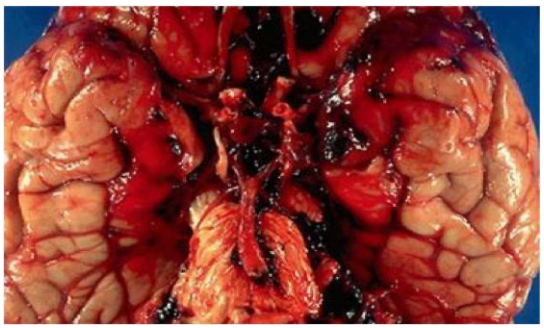

A. Thrombotic brain infarct
B. Embolic brain infarct
C. Rupture of AV malformation
D. Epidural hemorrhage
E. Ruptured berry aneurysm

Ans: E

5. A 62-year-old man is undergoing hip joint replacement. During this procedure, the anesthesiologist reports a drop-in blood pressure with hypotension that persists for 30 minutes despite intervention with pressor agents. Which of the following pathologic lesions is most likely to occur in his brain because of this prolonged hypotensive episode?

A. Frontal lobar hemorrhage
B. Lacunar infarct in corpus striatum
C. Hemorrhagic infarct in brain parenchyma
D. Embolic infarct in parietal lobe
E. Linear parasagittal infarction

Ans: E

6. A 53 year old patient presents with visual hallucinations, fluctuating cognitive function. On physical examination you notice that the patient has difficulty with starting movements, as well rigidity on passive movement. At rest he has a tremor, histological findings include intracellular eosinophilic inclusions, which of the following would be more likely diagnosis?

A. Lewy body dementia
B. Parkinson
C. Huntington
D. Alzheimer
E. Frontotemporal dementia

Ans: A

7. A patient presents to your clinic accompanied by his wife, who complains that her husband has been aggressive, rude, careless. " his behavior and personality aren't like him anymore " he's also been having difficulty with language. He recently also started moving slowly and had some accidental falls. Which of the following would be the more likely diagnosis ?

A. Parkinson's disease
B. Frontotemporal dementia
C. Huntington disease
D. Lewy body dementia
E. Alzheimer's disease

Ans: B

8. A 40-year-old woman with a history of multiple sclerosis presents with a complaint of recent onset of diplopia in all directions of gaze. On examination, you find that she has exotropia of both eyes on primary gaze and no voluntary horizontal adduction. Where do you localize her findings to?

A. Left (MLF) medial longitudinal fasciculus and right lateral gaze center (PPRF)
B. Bilateral lateral gaze centers (PPRF)
C. Right (MLF) medial longitudinal fasciculus and right lateral gaze center (PPRF)
D. Bilateral abducens nucleus (VI nerve)
E. Right and left (MLF) medial longitudinal fasciculus

Ans: E

9. A 21 year-old medical student who's been studying really hard for the past 2 months to score an A in her Neurology Block has been feeling really down, tired and easily irritable. On further questioning she admits to having difficulty sleeping at night, she's worried about letting her parents down and she's tired all the time. She also feels like her muscles are tense. When you ask her how she was doing before her Neurology block, she explains that she's felt this way for the past 2 semesters. Which of the following is the most underlying cause?

A. Panic disorder
B. Adjustment disorder
C. Generalized anxiety disorder
D. Agoraphobia
E. Acute stress disorder

Ans: C

10. A 30-year-old man has been easily distractible, impulsive with increased activity and is needing less sleep for the past 4 days. He has no visual or auditory hallucinations, his thoughts are not disorganized, and he has no delusions. His symptoms are not affecting his daily life, but upon further questioning you pick up that he has had a depressive episode lasting a couple of weeks. Which of the following is the most underlying cause?

A. Major depressive disorder
B. Bipolar II
C. Dysthymia
D. Bipolar I
E. Schizoaffective disorder

Ans: B

11. A 40 y/o man who's been living alone since his wife passed away 7 months ago has been feeling down, he is oversleeping, overeating, and feels his arms and his legs heavier than normal. He experienced an improved mood in response when his daughter visited. Which of the following is the most underlying cause?

A. Adjustment disorder
B. Depression with atypical features
C. Major depressive episode
D. Generalized anxiety disorder
E. Dysthymia

Ans: B

12. A 38-year-old man was brought into the emergency room at 1 am by a police officer for screaming nonsense in his neighborhood. For the past month the patient believes that everyone is out to get him, he thinks that the tv is talking to him and he is hearing voices that are telling him to run for his life even when the tv is turned off. Which of the following is the most likely underlying cause?

A. Bipolar 1
B. Bipolar 2
C. Schizophreniform disorder
D. Schizophrenia
E. Schizoaffective disorder

Ans: C

13. Which of the following is the most effective treatment for panic disorders?

A. psychodynamic psychotherapy
B. cognitive behavioral therapy
C. tricyclic antidepressants
D. combination of psychotherapy and pharmacotherapy
E. benzodiazepine

Ans: D

14. A 60-year old man heavy drinker has steadily worsened over the past several months. He noticed that he needed to to stand on with his feet far apart in order to maintain his balance and that he waddled when he walked. He has past pointing and dysdiadochokinesia on neurological examination. Which one of the following nuclei is involved in this case?

A. Vestibular nuclei
B. Caudate nucleus
C. Lentiform nucleus
D. Nucleus fastigii
E. Dentate nucleus

Ans: E

15. A 70-year old man developed stopped posture, masked facies, shuffling gait and pill rolling tremor in the right hand. Increased tonic discharge from which of the following structures is the cause of these symptoms ?

A. Dentate nucleus
B. Globus pallidus interna
C. Putamen
D. Caudate nucleus
E. Thalamus

Ans: B